

Alar Rim Grafting in Rhinoplasty

Indications, Technique, and Outcomes

Kofi D. O. Boahene, MD; Peter A. Hilger, MD

Objective: To determine the potential indications for placement of cartilaginous alar rim grafts in primary and revision septorhinoplasty.

Methods: Retrospective medical chart analysis of all patients undergoing septorhinoplasty from March 2003 through June 2004 in a private facial plastic and reconstructive surgery center and a tertiary teaching hospital. Patients who received alar rim grafts were identified. The indications for placement of the alar rim grafts were deduced from their preoperative evaluation and intraoperative assessment as noted in their comprehensive operative notes. Preoperative and postoperative digital photographs as well as postoperative medical records were analyzed for alar contour, pertinent patient complaints, and complications.

Results: During the 15-month study period, 150 patients underwent septorhinoplasty performed by the senior author. Of these patients, 31 received alar rim grafts. The most frequent indications for placement of alar rim grafts were cephalic malposition of the lower lateral cartilage with inadequate alar support (9 patients [29%]), correction of alar flare (9 patients [29%]), and correction of dynamic alar margin collapse (8 patients [26%]). At a mean 6-month follow-up, there were no graft displacements or extrusion.

Conclusion: Alar rim grafting is a simple and versatile approach to providing additional support to the external nasal valve and for improving nasal base contour.

Arch Facial Plast Surg. 2009;11(5):285-289

A

LAR RIM CONTOUR AND RESILIENCE play important roles in nasal tip aesthetics and function. Contour deformities and collapse of the alar rim may result from congenital weakness or malposition of the lower lateral cartilage (LLC). In addition, alar pinching and valve collapse may occur as a result of overzealous cephalic trimming of the LLC without compensatory measures. Alar asymmetries may be noticed in the early postoperative period or in a delayed manner as a result of scar contracture. Recent emphasis on nasal tip grafting and suturing techniques instead of cartilage excision has allowed more predictable control of the alar contour. Traditionally, structural and contour deformities of the alar rim have been addressed with batten grafts, strut grafts, composite grafts, and suture techniques.¹⁻³ A less conventional graft is the alar rim graft placed in a nonanatomic fashion along the alar margin. We determined the indications for alar rim grafting in rhinoplasty and reviewed the functional and aesthetic outcome in a series of patients.

Author Affiliations: Divisions of Facial Plastic and Reconstructive Surgery, Departments of Otolaryngology-Head and Neck Surgery, Johns Hopkins University School of Medicine, Baltimore, Maryland (Dr Boahene), and University of Minnesota, Minneapolis (Dr Hilger).

METHODS

ANATOMIC BASIS OF THE ALAR RIM GRAFT

The ideal alar rim transitions smoothly from the nasal tip defining point to the nasofacial insertion as a gentle line with a slight convexity (**Figure 1A**). The contour and strength of the alar rim is primarily determined by the semirigid lateral crus of the LLC. As the LLC transitions from the intermediate crus to the lateral crus, it diverges away from the alar margin to a more cephalad position. Thus, the posterior half of the alar is devoid of any rigid support (**Figure 2A**). This peculiar anatomic relationship between the LLC and the alar margin has several structural implications. A greater degree of cephalic rotation of the lateral crus, as seen in congenital LLC malposition, leaves more of the alar without rigid support (**Figure 2B**). Overzealous resection of the cephalic margin of the LLC reduces its support of the alar rim. The lack of rigid support along most of the alar rim leaves it vulnerable to inevitable scarring following trauma or rhinoplasty. A weak lateral crus will result in static or dynamic collapse of the alar rim during inspiration. As recently demonstrated,⁴ the aesthetically pleasing nasal tip highlights the nasal tip defining points, transition-

ing smoothly to the alar margin without an interrupting shadow. Dome suturing techniques commonly used in narrowing broad nasal tips often interrupt the alar margin and may result in a pinched nasal tip with an isolated nasal tip lobule. Analogous to a shirt collar stay, the alar rim graft is placed along the alar margin and is capable of directly altering the contour and strength of the alar margin and therefore improving the function and aesthetic harmony of the nasal tip (**Figure 3**).

PATIENTS AND DESIGN

From March 2003 through June 2004, 150 patients underwent rhinoplasty, with all procedures performed by the senior author (P.A.H.). Patients who received alar rim grafts were identified. The indications for placement of the alar rim grafts were deduced from their preoperative evaluation and intraoperative assessment as noted in their comprehensive operative reports. Preoperative and postoperative digital photographs, as well as postoperative medical records, were analyzed for alar contour stability or changes, pertinent patient complaints, and complications. Written informed consent was obtained from patients whose photographs were included in the final publication.

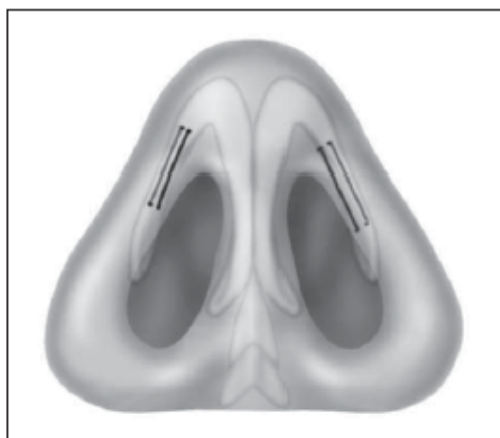


Figure 1. The ideal alar rim transitions smoothly from the nasal tip defining points to the nasofacial insertion as a gentle curve without a clear demarcation between the nasal tip and alar lobules.

The alar rim graft is placed in a tunnel created directly along the alar margin. First, the alar margin is infiltrated with an anesthetic solution for hydrodissection and vasoconstriction. The marginal incision and alar margin are exposed with a wide, double-pronged retractor. With the rim everted, a precise tunnel is dissected along the alar margin beginning from the medial end of the marginal incision to the alar base. Care is taken to avoid penetrating the alar skin. A precise alar tunnel can be safely created with a narrow-tipped scissor and Cottle dissector (**Figure 4**).

We most commonly fashion alar rim grafts from harvested quadrangular septal cartilage, but other sources of cartilage may be used. The dimensions of the rim graft are first determined by measuring along the alar margin the region that requires spanning. The rim graft is tailored on a case-by-case basis and measures 2 to 3 mm wide and 15 to 25 mm long. The edges of the rim graft should be beveled or contoured to reduce their profile and palpability. The medial edge of the rim graft is softened by gentle crushing with a Brown-Adson forceps or a cartilage morselizer.

Creating a tight and precise pocket minimizes migration of the alar rim graft. To further immobilize the rim graft, a 5.0 fast-absorbing suture is placed around the rim graft, fixing it to adjacent subcutaneous tissue at its medial end. Placing the suture through the thin rim graft often leads to cartilage fracture.

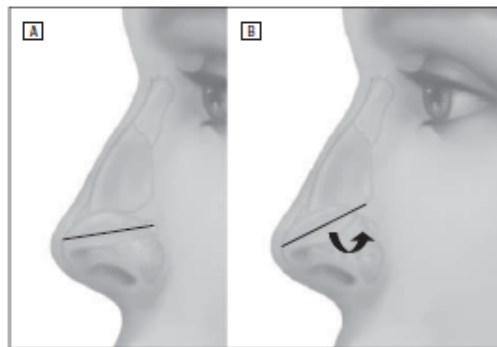


Figure 2. As the lower lateral cartilage transitions from the intermediate crus to the lateral crus, it diverges away from the alar margin to a more cephalad position. Thus, the posterior half of the alar is devoid of any rigid support (A). With cephalic rotation of the lower lateral crus, a greater portion of the alar is left without rigid support (B).

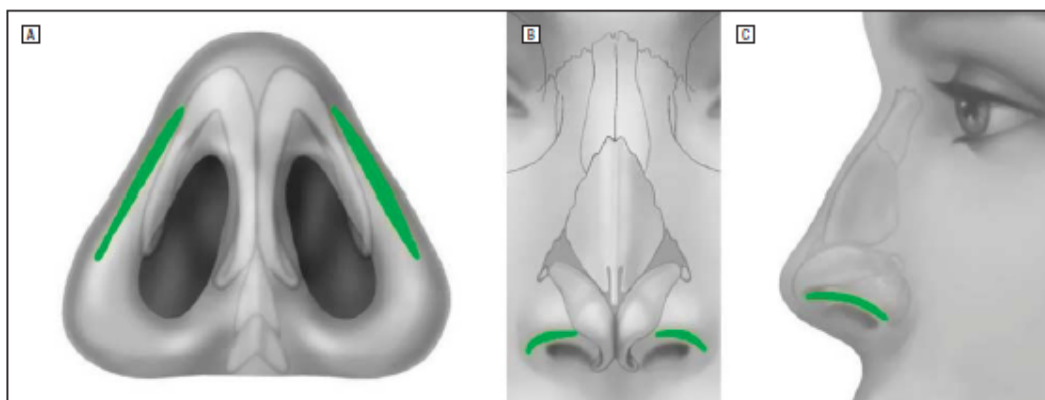


Figure 3. The alar rim graft (green) is placed directly along the alar margin to effect contour changes and provide resilience. A, Basal view; B, front view; and C, profile view.

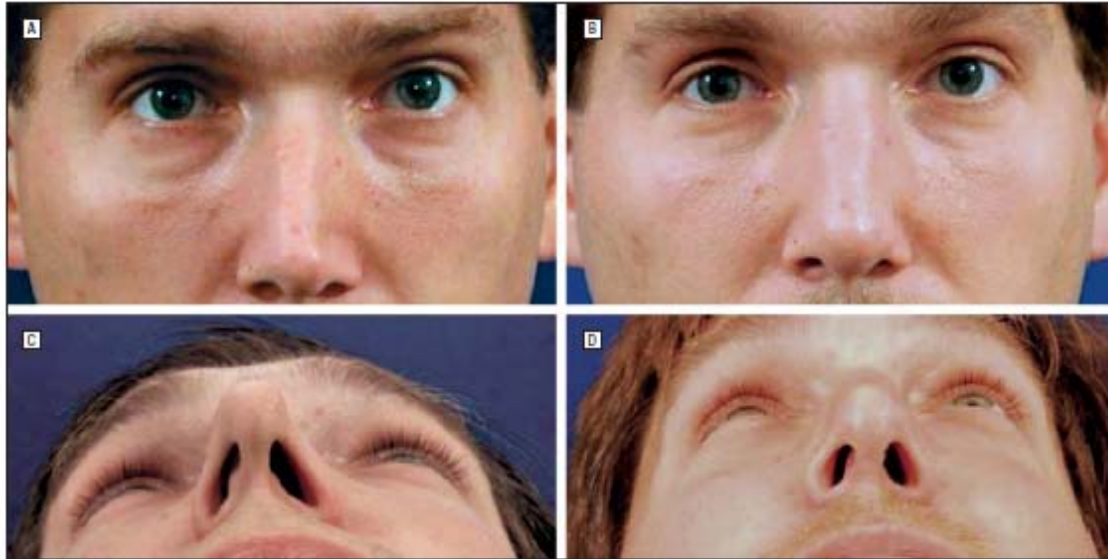


Figure 6. Case 2. Alar rim grafting placed to moderate the degree of alar flaring after deprojecting an overprojected nasal tip. The rim grafts also provide alar support against dynamic inspiratory collapse. A, Preoperative front view; B, postoperative front view; C, preoperative basal view; and D, postoperative basal view.

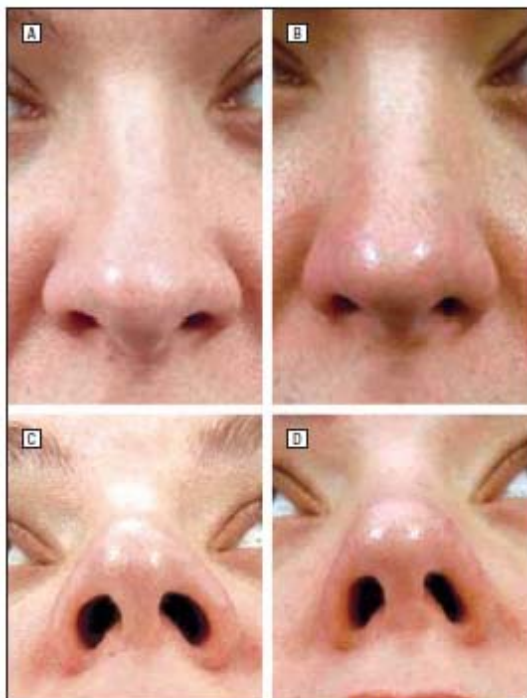

Figure 7. Case 3. Alar rim grafting for correction of mild alar flaring. A, Preoperative front view; B, postoperative front view; C, preoperative basal view; and D, postoperative basal view.

overprojected nasal tip with weak alar support, asymmetric alar contour, and dynamic external nasal valve collapse on inspiration. He underwent open septorhinoplasty with nasal tip deprojection. Bilateral alar rim grafts were placed to minimize alar flaring from nasal tip depro-

jection and also to provide added alar rim support against collapse. Clinical evaluation at the 12-month follow-up revealed improved alar rim support on inspiration and a more harmonious alar contour (Figure 6).

CASE 3

A 31-year-old Hispanic woman with a specific desire to reduce her alar flare presented for revision rhinoplasty (Figure 7). Preoperative nasal tip analysis revealed mild alar flaring and a diverging nostril axis. She underwent rhinoplasty through an open approach with placement of bilateral alar rim grafts alone without wedge resections for correction of alar flare. Basal views taken at her 12-month follow-up show improvement in the degree of alar flaring and a reoriented nostril axis (Figure 7).

COMMENT

In this study, the 2 most common indications for placement of alar rim grafts were cephalic malposition of the LLC and correction of alar margin flare. Additional indications included support of the alar rim from collapse, often seen in revision cases when the LLC was overresected or in patients with congenital weakness of the LLC. Alar rim grafts were also used to correct alar margin asymmetries, mild notching, and retraction.

Cephalic malposition of the LLC was first described by Sheen⁵ as displacement of the alar cartilage at the midpoint of the alar rim toward the medial canthus instead of laterally toward the lateral canthus. Clinically, the alar rim appears notched and boxy, an appearance classically described as the parenthesis sign (Figure 5). From a series of measurements made in 50 consecutive pa-

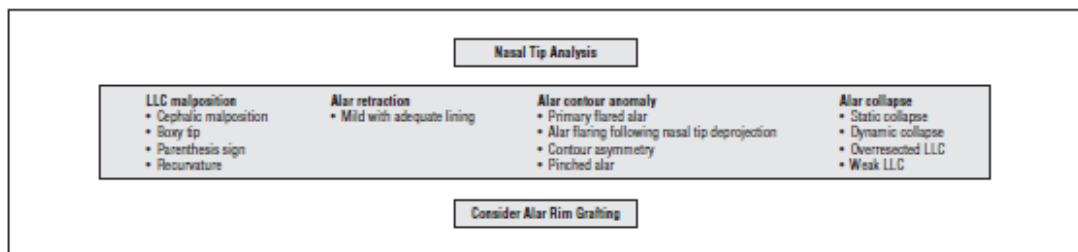


Figure 8. Nasal tip analysis and indications for alar rim grafting. LLC indicates lower lateral cartilage.

tients, Daniel⁶ noted that the location of the caudal margin of the lateral crus of the LLC 7 mm or more from the mid-alar margin highly correlates with malpositioning of the LLC. Cephalic malpositioning of the LLC leaves more of the alar without rigid support. Preoperatively and intraoperatively, it is important to identify this variant of LLC orientation, especially when cephalic trimming is being considered. Injudicious cephalic trimming in a malpositioned LLC has the potential to leave a weakened LLC, which over time will succumb to contractural forces of scarring. Prophylactic placement of alar rim grafts provides additional rim support and corrects the alar notching typically seen.

Alar flaring is a common complaint in patients seeking cosmetic nasal tip rhinoplasty. It can be either congenital or secondary to deprojection of an overprojected nasal tip. Alar flaring has been traditionally addressed with alar wedge resection.⁷ In this study, alar flaring was improved with either rim graft alone or in combination with wedge resection. Combining rim grafts with wedge resection was safely performed in 5 of 9 patients without any increased risk of infection or graft loss. The analogy of a collar stay applies here, whereby the placement of a stiff alar rim graft straightens a flared alar or minimizes the degree of secondary flaring resulting from nasal tip deprojection.

The use of alar rim grafts in the correction of alar notching or retraction is a viable option in mild cases (those with approximately 3–4 mm of retraction) when there is adequate lining and skin elasticity to allow stretching and unfurling of the retracted rim.⁸ Alar rim grafts can also be used to reduce the relative alar retraction that occurs when septal extension grafts are used to lengthen short noses. For more severe cases of notching or retraction, more aggressive maneuvers, including the use of composite grafts, alar batten grafts, and lateral crural strut grafts, may be needed.

In summary, alar rim grafting is a simple and versatile approach to providing additional support to the external nasal valve and improving nasal base harmony. It should be considered in primary or secondary rhinoplasties when nasal tip analysis reveals malpositioned LLC,

alar flaring, overprojected nasal tips, mild retraction, and contour asymmetries (**Figure 8**).

Accepted for Publication: April 7, 2009.

Correspondence: Kofi D. O. Boahene, MD, Division of Facial Plastic and Reconstructive Surgery, Department of Otolaryngology–Head and Neck Surgery, Johns Hopkins University School of Medicine, 601 N Caroline St, Sixth Floor, Baltimore, MD 21878 (dboahen1@jhmi.edu).

Author Contributions: Study concept and design: Boahene and Hilger. Acquisition of data: Boahene. Analysis and interpretation of data: Boahene. Drafting of the manuscript: Boahene. Critical revision of the manuscript for important intellectual content: Boahene and Hilger. Administrative, technical, and material support: Boahene and Hilger. Study supervision: Hilger.

Financial Disclosure: Dr Hilger has been a consultant to Medtronic.

Previous Presentation: This study was presented at the Fall Meeting of the American Academy of Facial Plastic and Reconstructive Surgery; September 25, 2005; Los Angeles, California.

REFERENCES

1. Toriumi DM, Josen J, Weinberger M, Tardy ME Jr. Use of alar batten grafts for correction of nasal valve collapse. *Arch Otolaryngol Head Neck Surg.* 1997;123(8):802–808.
2. Gunter JP, Friedman RM. Lateral crural strut graft: technique and clinical application in rhinoplasty. *Plast Reconstr Surg.* 1997;99(4):943–952.
3. Kamer FM, McQuown SA. Mincocomposite graft for nasal alar revision. *Arch Otolaryngol Head Neck Surg.* 1987;113(9):943–949.
4. Toriumi MD. New concepts in nasal tip contouring. *Arch Facial Plast Surg.* 2006; 8(3):156–185.
5. Sheen JH. *Aesthetic Rhinoplasty*. St Louis, MO: CV Mosby; 1978:264–265.
6. Daniel RK. Discussion: the two essential elements for planning tip surgery in primary and secondary rhinoplasty: observation based on review of 100 consecutive patients. *Plast Reconstr Surg.* 2004;114(6):1582–1585.
7. Constantian MB. The two essential elements for planning tip surgery in primary and secondary rhinoplasty: observations based on review of 100 consecutive patients. *Plast Reconstr Surg.* 2004;114(6):1571–1581.
8. Brissett AE, Sherris DA. Changing the nostril shape. *Fac Plast Clin North Am.* 2000; 8:433–445.

RESULTS

From May 2003 through December 2004, 150 consecutive rhinoplasties were performed by the senior author. Of these, 31 cases with alar rim grafting were identified. There were 26 cases of primary rhinoplasty and 5 revision cases. There were 22 females and 9 males ranging in age from 15 to 61 years. The most frequent indications for placement of alar rim grafts were cephalic malposition of the LLC (9 cases [29%]) and correction of alar flare (9 cases [29%]). Other indications included dynamic collapse of the external nasal valve (8 cases [26%]), alar retraction or notching (3 cases [10%]), and alar contour asymmetry (2 cases [6%]). Among the revision cases, the most common rea-

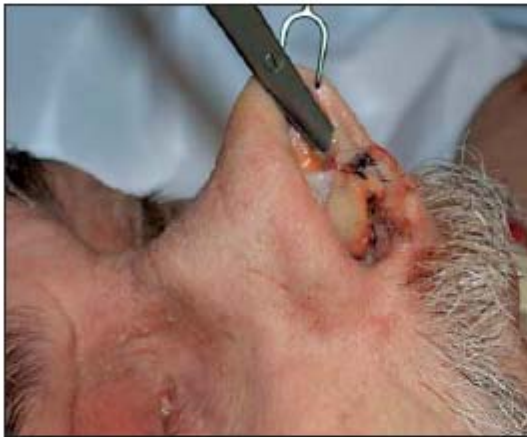

Figure 4. Alar rim grafts can be placed through the marginal incision by creating a pocket along the alar margin.

son for placing alar rim grafts was alar retraction (3 of 5 cases). Alar rim grafts alone were used to correct alar flaring in 5 of 9 cases but were combined with wedge resection of the alar in 4 of 9 cases. At follow-up (mean duration of follow-up, 26 months; range, 6-35 months) there were no graft infections, displacements, or extrusion. No patient complained of a stiff alar rim. Among the patients with preoperative dynamic collapse of the alar margin, there was notable improvement in alar support with diminished collapse on deep inspiration.

CASE 1

A 35-year-old white woman presented for primary rhinoplasty and improved nasal tip definition. Nasal tip analysis revealed cephalic malposition of the LLC with the classic "parenthesis sign" (Figure 5). It was noted that her alar rim transition from the nasal tip defining point to the alar margin was interrupted by a depression. She underwent open septorhinoplasty with nasal tip refinement techniques that included cephalic trimming of the lateral crus. Bilateral alar rim grafts were placed to support the alar and create an uninterrupted transition from the nasal tip to alar lobules. Postoperative images taken at the 12-month follow-up show improvement of the alar margin contour with an uninterrupted transition from the nasal tip defining points to the alar lobule. In addition, there is less alar flaring. Clinically, the patient had good alar margin support on deep inspiration and on palpation.

CASE 2

A 35-year-old white man presented for primary septorhinoplasty (Figure 6). Nasal tip analysis revealed an

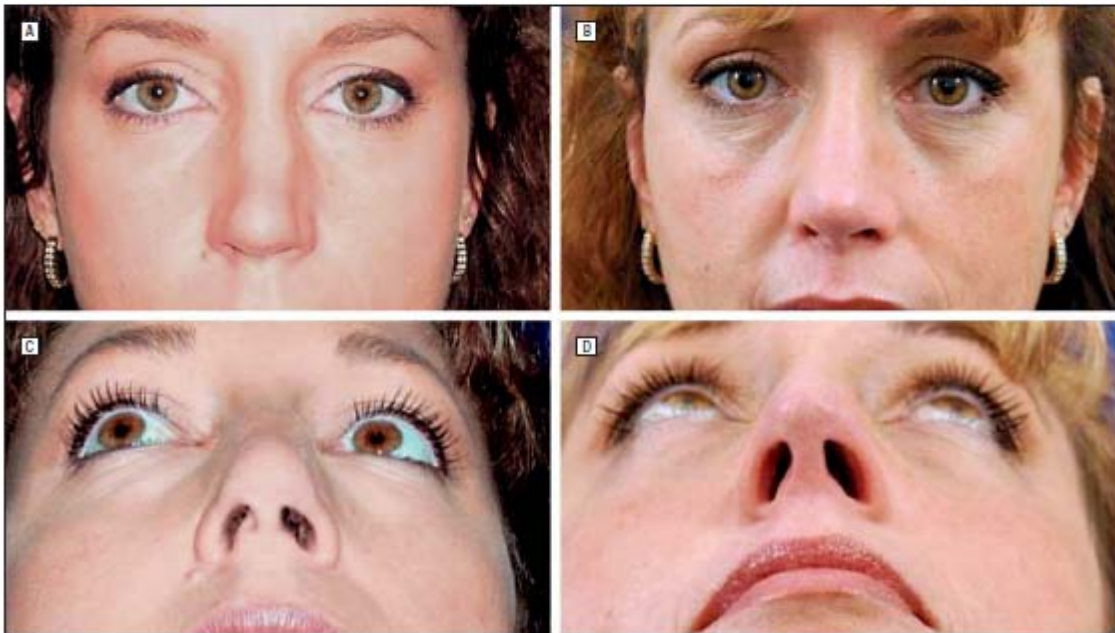

Figure 5. Case 1. Alar rim grafting for alar margin support and contour correction in a patient with cephalic malpositioned lower lateral cartilages and "boy" nasal tip. A, Preoperative front view; B, postoperative front view; C, preoperative basal view; and D, postoperative basal view.